

CASE REPORT

Exogenous steroid-induced hypoadrenalism in a person living with HIV caused by a drug–drug interaction between cobicistat and intrabursal triamcinolone

Navnit Makaram,¹ Clark D Russell,² Simon Benedict Roberts,¹ Jarrad Stevens,³ Gavin Macpherson¹

¹Department of Orthopaedics and Trauma, Royal Infirmary of Edinburgh, Edinburgh, UK

²Department of Infectious Diseases and Medical Microbiology, University of Edinburgh MRC Centre for Inflammation Research, Edinburgh, UK

³Department of Orthopaedics and Trauma, Royal Infirmary of Edinburgh, Edinburgh, UK

Correspondence to

Dr Jarrad Stevens, drjarradstevens@hotmail.com

Accepted 22 November 2018

SUMMARY

We report a diagnosis of exogenous steroid-induced hypoadrenalism in a person living with HIV caused by a drug–drug interaction (DDI) between intrabursal triamcinolone and the pharmacokinetic booster cobicistat. A 53-year-old woman living with HIV, managed with dolutegravir and cobicistat-boosted darunavir, presented to the orthopaedic clinic with worsening hip pain. She was diagnosed with greater trochanteric pain syndrome (GTPS) of the hip and was treated with intrabursal injection of bupivacaine and triamcinolone. Seven days following this injection, she presented with Cushingoid features, an undetectable cortisol and was diagnosed with exogenous steroid-induced hypoadrenalism. Cobicistat is a cytochrome P450 3A inhibitor and in this case inhibited clearance of intrabursal triamcinolone, leading to exogenous glucocorticoid excess and adrenal suppression. This is the first report to describe this predictable DDI with cobicistat following intrabursal glucocorticoid injection. This case highlights the complexities in managing non-HIV-related chronic morbidities in people living with HIV.

BACKGROUND

Intra-articular and intrabursal injection of steroid is a common and established treatment for hip pain due to osteoarthritis and for associated conditions such as greater trochanteric pain syndrome (GTPS).^{1–4} GTPS is the cause of hip pain in 10%–20% of patients presenting with hip pain to primary care, with an incidence of 1.8 patients per 1000 per year.⁵ Triamcinolone acetate is the second most frequently used glucocorticoid preparation for intra-articular and periarticular steroid injection, accounting for 31% of steroid injections. Methylprednisolone acetate is the most frequently used glucocorticoid, comprising 35% of injections.⁶ Contraindications to intra-articular or periarticular glucocorticoid injection include periarticular infection, septic arthritis, periarticular fracture, known hypersensitivity to drug components and previous adverse drug reaction.⁶ Pharmacological interactions are a more common consideration for patients undergoing an intra-articular or periarticular glucocorticoid injection. Anticoagulants, hepatic

inducers/inhibitors, drugs affecting plasma potassium levels, diabetic medications, antihypertensive medications and neuromuscular blocking agents must all be taken into consideration.⁷ Interactions can lead to immunosuppression, adrenal suppression and mood changes resulting from fluctuations in circulating hormonal concentrations due to metabolic interactions.⁷ Such interactions are rarely reported with locally administered depot glucocorticoid preparations.

The efficacy of modern antiretroviral (ARV) therapy (ART) has effected dramatic increases in life expectancy for people living with HIV (PLWH) who have access to these drugs.⁸ In addition, European surveillance data from 2004 to 2015 demonstrated a significant increase in the rate of new HIV diagnoses in older adults (age ≥ 50 years).⁹ Therefore, new challenges exist in the management of HIV throughout the life course, including the management of non-HIV-related chronic morbidity in older patients. This includes hip pain due to primary and secondary Osteoarthritis (OA) or associated soft tissue pathologies. Intra-articular and periarticular glucocorticoid injection is frequently used as an early diagnostic and/or therapeutic intervention in such cases.^{3,4}

This case report documents the development of exogenous steroid-induced hypoadrenalism in a PLWH caused by a drug–drug interaction (DDI) between the CYP3A inhibitor cobicistat and

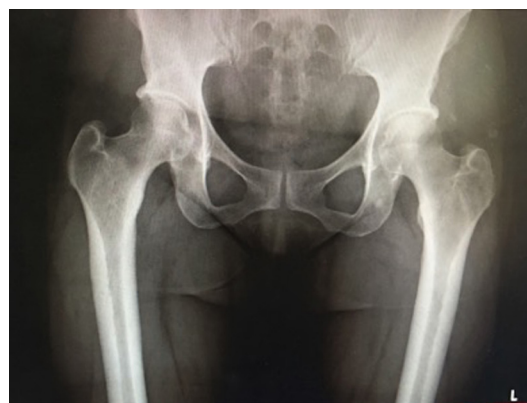
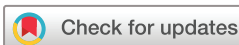
Figure 1 AP radiograph of the patient's pelvis and hips.



© BMJ Publishing Group Limited 2018. No commercial re-use. See rights and permissions. Published by BMJ.

To cite: Makaram N, Russell CD, Roberts SB, et al. *BMJ Case Rep* 2018;**11**:e226912. doi:10.1136/bcr-2018-226912

Unexpected outcome (positive or negative) including adverse drug reactions

Table 1 Differential diagnosis of Cushing's syndrome and related glucocorticoid disorders

ACTH-dependent	ACTH-independent	Pseudo-Cushing's syndromes
Cushing's disease pituitary dependant 70%	Adrenal adenoma (10%) and carcinoma (5%–10%)	Alcoholism
Ectopic ACTH syndrome 5%–10%	McCune-Albright Syndrome (rare)	Depression
Ectopic CRH syndrome (rare)	Bronchial carcinoid tumour	Obesity
Macronodular adrenal hyperplasia <5%	Small-cell lung cancer	Polycystic ovarian syndrome
Iatrogenic (treatment with 1–24 ACTH) (rare)	Medullary thyroid carcinoma	
	Iatrogenic exogenous glucocorticoid excess—rare*	

*Relates to cause in our case.

ACTH, Adrenocorticotropic hormone; CRH, corticotropin releasing hormone.

intrabursal triamcinolone injection around the hip for treatment of GTPS.

CASE PRESENTATION

A 53-year-old woman with virologically suppressed HIV (viral load <40 copies/mL, CD4 count 837 cells/mL), managed with dolutegravir and cobicistat-boosted darunavir (DRV/c), presented with left hip pain of several years' duration. Clinical examination demonstrated localised tenderness over the left greater trochanter, and tenderness that was maximal over the greater trochanter in hip flexion, adduction and internal rotation. Her range of movement at the hip was essentially normal, and there was no sign of fixed flexion deformity or limb length discrepancy. An Anteroposterior (AP) radiograph as seen in [figure 1](#) revealed no degenerative changes of the left hip joint, and she was diagnosed with left hip trochanteric bursitis. Her pain was persistent and intrusive despite simple analgesia, and she opted for a therapeutic trial of glucocorticoid injection and subsequent physiotherapy. She had received a glucocorticoid injection 3 years previously for a subacromial bursitis, before commencing DRV/c, with no adverse effects. Under sterile conditions and after obtaining informed consent, 40 mg of triamcinolone acetonide (mixed with 5 mL 0.5% bupivacaine) was injected in the region of the left greater trochanteric bursa with relief of pain and no immediate complications. The patient was then discharged to the care of the physiotherapists for gluteal strengthening exercises.

Seven days following the glucocorticoid injection, she re-presented to the emergency department with new-onset facial and neck swelling of 2 days' duration. She also reported fatigue and easy bruising. Examination revealed tissue oedema extending from the face to the upper posterior thorax causing a 'hump' appearance and dorsal fat pad. She was also markedly short of breath on minimal exertion with upper and lower limb peripheral oedema. Her oxygen saturations were satisfactory (>94% on room air), and chest auscultation was normal.

INVESTIGATIONS

Full blood count, C reactive protein, biochemistry and thyroid function tests were within normal limits. Baseline cortisol was <40 nmol/L increasing to 165 nmol/L 1 hour after intramuscular administration of 250 µg Synacthen, diagnostic of adrenal insufficiency. Twenty-four-hour urinary cortisol level was within normal limits (85 mmol/per 24 hours). A chest radiograph, ECG and echocardiogram showed no significant abnormalities. An ultrasound scan of her neck revealed prominence of the subcutaneous tissues, but no pathological lesions. She remained non-feverish throughout the admission. Measurement of circulating triamcinolone was not available.

DIFFERENTIAL DIAGNOSIS

The differential diagnosis for the constellation of symptoms and signs included Cushing's syndrome and related disorders which can be classified as shown in [table 1](#). An algorithm used to identify the diagnosis is illustrated in [figure 2](#).

TREATMENT

Our patient required supportive therapy with fluid resuscitation (intravenous Hartmann's), as per local departmental protocol and due to clinical signs of hypovolaemia including decreased urine output, analgesia and bed-rest with regular observation. No changes were made to her ART. In view of the diagnosis of adrenal insufficiency, advice was given regarding 'sick day' rules, and a supply of oral hydrocortisone was provided for use in the event of an intercurrent infection.

OUTCOME AND FOLLOW-UP

A diagnosis of exogenous steroid-induced hypoadrenalism secondary to CYP3A inhibition by cobicistat causing impaired clearance of the intrabursal injection of triamcinolone was made. The patient was discharged 2 days after admission, and her Cushingoid signs and symptoms progressively resolved. She was followed in the endocrinology clinic, and her most recent short Synacthen test demonstrates recovery of adrenal function (baseline cortisol 302 nmol/L increasing to 567 nmol/L after stimulation). Her ART remains unchanged.

DISCUSSION

In the context of near normal life expectancy for PLWH receiving ART, an important aspect of managing HIV is the management of non-HIV-related chronic morbidity. This case illustrates the potential complexities in doing so when unfamiliar with ARV pharmacology.

One component of this patient's ART was a protease inhibitor (darunavir) combined with the pharmacokinetic booster cobicistat. Pharmacokinetic boosters are used to inhibit metabolism of the boosted drug to allow dose reduction and thus reduce side effects and pill burden. Cobicistat is derived from the protease inhibitor ritonavir, but lacks a hydroxyl group and does not have any HIV protease inhibitory activity. The mechanism of pharmacokinetic boosting by cobicistat (like ritonavir when used at lower doses as a pharmacokinetic booster) is potent inhibition of the cytochrome P450 3A isoenzyme.^{10 11} This inhibits metabolism of coadministered protease inhibitors (such as darunavir in this case) but also any other drug metabolised by this pathway, including glucocorticoids. Impaired glucocorticoid clearance through this mechanism has been reported for cobicistat and ritonavir, when glucocorticoids have been administered through the oral, inhaled, intranasal and intra-articular routes.^{12–21}

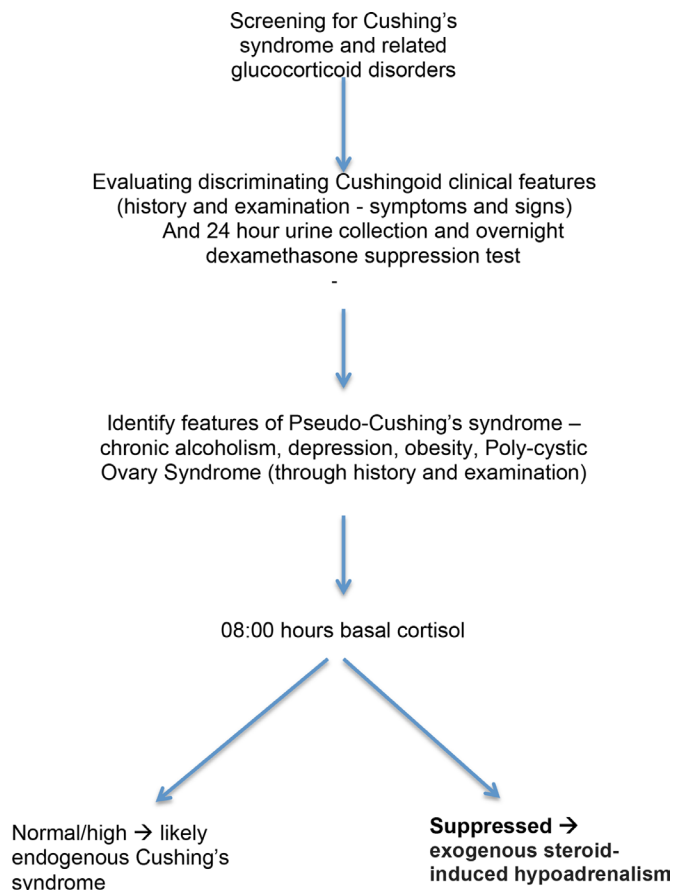


Figure 2 Algorithm for the diagnosis of endogenous versus exogenous Cushing's syndrome (note ** relates to cause of Cushing's in our case).

Although we could find no reports of this occurring during coadministration of cobicistat and intrabursal glucocorticoid injection, a case report does document exogenous steroid-induced hypoadrenalism following interlaminar triamcinolone injection in a patient on an ARV regimen containing cobicistat.²²

Corticosteroids are an effective therapy for a variety of inflammatory and autoimmune conditions but come with risks of adverse effects. Several such adverse effects of corticosteroids were observed in our patient, including Cushingoid appearance: buffalo hump and facial swelling; and evidence of adrenal insufficiency.

Triamcinolone is used commonly in intra-articular and peri-articular injections and is commonly employed in GTPS.²³ Although the systemic half-life of triamcinolone is approximately 3 hours,^{23 24} it can be as long as 40 days.²⁵ It has been reported that CYP3A inhibitors such as cobicistat and ritonavir are estimated to prolong the elimination half-life of triamcinolone in an epidural formulation by around 170-fold by its inhibitive action.¹⁹

In our patient, the symptoms and signs identified were consistent with those previously described in exogenous glucocorticoid excess, namely facial and neck swelling, general fatigue and malaise.^{19 26-29} Cases of iatrogenic adrenal suppression presenting in PLWH in an immunodeficient state with a normal CD4 count have previously been described but this is not observed in our patient.^{26 28 30 31} Jakeman *et al* reported oral candidiasis and herpes manifesting as a part of the immune suppression associated with exogenous glucocorticoid excess.³² Other clinical

signs include hypertension, hyperglycaemia and adrenal insufficiency.^{19 31 33}

The patient denied during the entire period of symptom onset any change in diet or commencement of any novel vitamin or nutrient supplements which presumed an exclusion of food or nutrients contributing to this adverse drug reaction. However, the authors do acknowledge there is no objective method to exclude this undertaken.

A further limitation of our study is the lack of measurements of intra-articular or blood concentration of triamcinolone following injection. A brief literature search did not reveal any further information regarding intracirculation concentrations in this regard. Further studies could employ such measurements to determine the effect of such intra-articular injections on the level of triamcinolone in the systemic circulation, and thus correlate increases in systemic concentration of steroid with clinical manifestation of symptoms and signs. Furthermore, a specific diagnostic test to determine the DDI observed in this study was not employed, and was, to our knowledge, unavailable. However, cortisol measurements pre-Synacthen and post-Synacthen stimulation provided the diagnosis of adrenal insufficiency.

Our case highlights the challenges for non-HIV-specialist clinicians in managing the chronic non-HIV-associated morbidity in PLWH and the necessity for all clinicians to be aware of the invaluable Liverpool HIV Drug Interactions checker.³⁴ Intrabursal injection of triamcinolone for the treatment of GTPS resulted in exogenous steroid-induced hypoadrenalism due to CYP3A inhibition caused by pharmacokinetic booster cobicistat in a patient receiving ART including DRV/c. This report confirms that like ritonavir, cobicistat-mediated CYP3A inhibition will result in impaired clearance of glucocorticoids even when not administered systemically.^{19 26-29} It is the first report of this occurring following an intrabursal injection of glucocorticoid. The effects of exogenous glucocorticoid excess and adrenal insufficiency can be significant, and our patient reported severe psychological distress from the disfigurement of increased adiposity in her face, neck and upper back but importantly no morbidity associated with hypoadrenalism occurred. While these effects are resolving, they are still evident several months after the initial drug interaction. The fatigue and malaise that our patient experienced led to several lost working weeks and a depressed mood.

The literature also reveals other symptoms and signs of this drug-drug reaction which are important to be aware of, but has not presented in our patient. Jakeman *et al* reported oral candidiasis and herpes manifesting as a part of the immune suppression associated with exogenous glucocorticoid excess in a similar intrabursal injection into the shoulder.³² Other clinical signs include hypertension, hyperglycaemia and adrenal insufficiency.^{10 29 30}

MANAGEMENT

Management strategies initially involve symptomatic relief and prevention of further complications. Patients should therefore avoid further corticosteroid injections.¹⁹ Alternative corticosteroids may be considered in accordance with the American College of Rheumatology. Other validated depot glucocorticoid preparations include methylprednisolone acetate and betamethasone. Maviki *et al* suggested the use of reduced dose methylprednisolone as a suitable alternative.²⁹ However, these reports illustrate the management strategies when ritonavir is employed.

In our patient, adrenal recovery occurred spontaneously without the need for steroid replacement, though the patient

was advised about 'sick day' rules. No changes to the patient's ART were required.

CONCLUSION

Through inhibition of CYP3A, the pharmacokinetic boosting agents ritonavir and cobicistat can impair clearance of oral, inhaled and injected glucocorticoids such as triamcinolone resulting in exogenous steroid-induced hypoadrenalism. Our report documents the first example of this following intrabursal injection of triamcinolone in a patient receiving DRV/c. This should be of particular interest to general practitioners, sports physicians, rheumatologists, orthopaedic surgeons and physiotherapists who treat musculoskeletal disorders that may require a corticosteroid injection. Importantly, all clinicians prescribing for PLWH should check any new drug using the Liverpool HIV Drug Interactions checker to identify potential DDI such as this one.

Learning points

- ▶ People living with HIV (PLWH) receiving antiretroviral therapy can have a near normal life expectancy, therefore older PLWH are increasingly presenting to healthcare providers due to non-HIV-related chronic conditions such as osteoarthritis.
- ▶ Cobicistat and ritonavir are pharmacokinetic boosters that inhibit the cytochrome P450 3A isoenzyme to increase the drug exposure of protease inhibitors to allow dose reduction and thus reduce side effects and pill burden. CYP3A inhibition will also reduce clearance of other drugs metabolised by this pathway, including glucocorticoids.
- ▶ Coadministration of a CYP3A inhibitor such as cobicistat with a glucocorticoid (even when not administered systemically) can cause a drug–drug interaction resulting in exogenous steroid-induced hypoadrenalism.
- ▶ All clinicians caring for PLWH should consult the Liverpool HIV Drug Interactions checker before prescribing a new medication (<https://www.hiv-druginteractions.org/>).

Contributors NM, SBR, JS and MacPherson were involved in data collection, literature review, drafting and finalising the manuscript. CDR provided invaluable Infectious diseases specialty expertise, providing extensive contribution through the rewriting and adapting of the manuscript in response to the reviewer's comments.

Funding The authors have not declared a specific grant for this research from any funding agency in the public, commercial or not-for-profit sectors.

Competing interests None declared.

Patient consent for publication Obtained.

Provenance and peer review Not commissioned; externally peer reviewed.

REFERENCES

- 1 Smith DL, McAfee JH, Lucas LM, et al. Treatment of nonseptic olecranon bursitis. A controlled, blinded prospective trial. *Arch Intern Med* 1989;149:2527.
- 2 Buchbinder R, Green S, Youd JM. Corticosteroid injections for shoulder pain. *Cochrane Database Syst Rev* 2003;CD004016.
- 3 Johnston CA, Wiley JP, Lindsay DM, et al. Iliopsoas bursitis and tendinitis. A review. *Sports Med* 1998;25:271–83.
- 4 Parziale JR, O'Donnell CJ, Sandman DN. Iliopsoas bursitis. *Am J Phys Med Rehabil* 2009;88:690–1.
- 5 Speers CJ, Bhogal GS. Greater trochanteric pain syndrome: a review of diagnosis and management in general practice. *Br J Gen Pract* 2017;67:479–80.
- 6 Centeno LM, Moore ME. Preferred intraarticular corticosteroids and associated practice: a survey of members of the American College of Rheumatology. *Arthritis Care Res* 1994;7:151–5.

- 7 Triamcinolone Acetonide. National Institute for Health and Care Excellence. British National Formulary. <https://bnf.nice.org.uk/drug/triamcinolone-acetonide.html> (Accessed 22 Mar 2018).
- 8 Sabin CA. Do people with HIV infection have a normal life expectancy in the era of combination antiretroviral therapy? *BMC Med* 2013;11:251.
- 9 Tavoschi L, Gomes Dias J, Pharris A. EU/EEA HIV Surveillance Network. New HIV diagnoses among adults aged 50 years or older in 31 European countries, 2004-15: an analysis of surveillance data. *Lancet HIV* 2017;4:e514–21.
- 10 Kempf DJ, Marsh KC, Kumar G, et al. Pharmacokinetic enhancement of inhibitors of the human immunodeficiency virus protease by coadministration with ritonavir. *Antimicrob Agents Chemother* 1997;41:654–60.
- 11 Zeldin RK, Petruschke RA. Pharmacological and therapeutic properties of ritonavir-boosted protease inhibitor therapy in HIV-infected patients. *J Antimicrob Chemother* 2004;53:4–9.
- 12 Walker-Bone K, Doherty A, Sanyal K, et al. Assessment and management of musculoskeletal disorders among patients living with HIV. *Rheumatology* 2017;10:1648–61.
- 13 Penzak SR, Formentini E, Alfaro RM, et al. Prednisolone pharmacokinetics in the presence and absence of ritonavir after oral prednisone administration to healthy volunteers. *J Acquir Immune Defic Syndr* 2005;40:573–80.
- 14 Foisy MM, Yakiwchuk EM, Chiu I, et al. Adrenal suppression and Cushing's syndrome secondary to an interaction between ritonavir and fluticasone: a review of the literature. *HIV Med* 2008;9:389–96.
- 15 Dupont C, Giraud V, Leporrier J, et al. Cushing's syndrome induced by combined treatment with inhaled fluticasone and oral ritonavir. *Case Rep* 2009;7:779–82.
- 16 Canalejo E, Pacheco MS. Cushing syndrome due to ritonavir-fluticasone interaction. *CMAJ* 2012;184:184.
- 17 Kedem E, Shahar E, Hassoun G, et al. Iatrogenic Cushing's syndrome due to coadministration of ritonavir and inhaled budesonide in an asthmatic human immunodeficiency virus infected patient. *Case Rep* 2010;47:830–1.
- 18 Lv Z, Chu Y, Wang Y. HIV protease inhibitors: a review of molecular selectivity and toxicity. *Hiv Aids* 2015;7:95–104.
- 19 Ramanathan R, Pau AK, Busse KH, et al. Iatrogenic Cushing syndrome after epidural triamcinolone injections in an HIV type 1-infected patient receiving therapy with ritonavir-lopinavir. *Clin Infect Dis* 2008;47:e97–9.
- 20 Weller IV, Williams IG. ABC of AIDS. Antiretroviral drugs. *BMJ* 2001;322:1410–2.
- 21 Schimmer BP, Funder JW. In: Bruton L, ed. *ACTH, adrenal steroids, and pharmacology of the adrenal cortex, in Goodman & Gilman's the pharmacologic basis of therapeutics*. 12th edn, 2011.
- 22 Wassner C, Maiti S, Kodroff K, et al. Iatrogenic adrenal insufficiency secondary to combination therapy with Elvitegravir/Cobicistat/Tenofovir Disoproxil Fumarate/ Emtricitabine and Interlaminar Triamcinolone Injection in an AIDS Patient. *J Int Assoc Provid AIDS Care* 2017;16:535–9.
- 23 Reid D. The management of greater trochanteric pain syndrome: a systematic literature review. *J Orthop* 2016;13:15–28.
- 24 Argenti D, Colligon I, Heald D, et al. Nasal mucosal inflammation has no effect on the absorption of intranasal triamcinolone acetonide. *J Clin Pharmacol* 1994;34:854–8.
- 25 Derendorf H, Möllmann H, Grüner A, et al. Pharmacokinetics and pharmacodynamics of glucocorticoid suspensions after intra-articular administration. *Clin Pharmacol Ther* 1986;39:313–7.
- 26 Sadarangani S, Berg ML, Mauck W, et al. Iatrogenic cushing syndrome secondary to ritonavir-epidural triamcinolone interaction: an illustrative case and review. *Interdiscip Perspect Infect Dis* 2014;2014:1–7.
- 27 Hall JJ, Hughes CA, Foisy MM, et al. Iatrogenic Cushing syndrome after intra-articular triamcinolone in a patient receiving ritonavir-boosted darunavir. *Int J STD AIDS* 2013;24:748–52.
- 28 Schwarze-Zander C, Klingmüller D, Klümper J, et al. Triamcinolone and ritonavir leading to drug-induced Cushing syndrome and adrenal suppression: description of a new case and review of the literature. *Infection* 2013;41:1183–7.
- 29 Maviki M, Cowley P, Marmery H. Injecting epidural and intra-articular triamcinolone in HIV-positive patients on ritonavir: beware of iatrogenic Cushing's syndrome. *Skeletal Radiol* 2013;42:313–5.
- 30 John G, Ollo D, Meyer P, et al. Pulmonary embolism and iatrogenic Cushing's syndrome after co-administration of injected-triamcinolone and ritonavir. *AIDS* 2013;27:2827–8.
- 31 Fessler D, Beach J, Keel J, et al. Iatrogenic hypercortisolism complicating triamcinolone acetone injections in patients with HIV on ritonavir-boosted protease inhibitors. *Pain Physician* 2012;15:489–93.
- 32 Jakeman B, Conklin J, Bouchonville M, et al. Iatrogenic Cushing's syndrome after triamcinolone plus ritonavir-boosted atazanavir. *J Am Pharm Assoc* 2015;55:193–7.
- 33 Panel on Antiretroviral Guidelines for Adults and Adolescents. *Guidelines for the use of antiretroviral agents in HIV-1-infected adults and adolescents*. Washington, DC: Department of Health and Human Services, 2018. (Accessed 21 Mar 2018).
- 34 University of Liverpool. HIV drug interactions checker. 2018. <https://www.hiv-druginteractions.org/checker> (Accessed 1 Nov 2018).

Copyright 2018 BMJ Publishing Group. All rights reserved. For permission to reuse any of this content visit <https://www.bmj.com/company/products-services/rights-and-licensing/permissions/>
BMJ Case Report Fellows may re-use this article for personal use and teaching without any further permission.

Become a Fellow of BMJ Case Reports today and you can:

- ▶ Submit as many cases as you like
- ▶ Enjoy fast sympathetic peer review and rapid publication of accepted articles
- ▶ Access all the published articles
- ▶ Re-use any of the published material for personal use and teaching without further permission

For information on Institutional Fellowships contact consortiasales@bmjgroup.com

Visit casereports.bmj.com for more articles like this and to become a Fellow